CASE REPORT

Prenatal Diagnosis of Ebstein's anomaly using Spatio-temporal image correlation (STIC) technique.

Mukesh Mittal*, Pankaj K Nitharwal, Abhinav Mathur***, Bajrang Lal Bishnoi******

ABSTRACT

Ebstein's anomaly is a congenital heart disease. Cause of this anomaly is failure of delamination of the tricuspid valve which results in apical displacement of septal and posterior leaflets of tricuspid valve. The valve is abnormal in position and in morphology. It is usually thickened and incompetent leading to tricuspid regurgitation and tricuspid stenosis to a lesser extent. The prognosis of this anomaly is poor and it results in fetal hydrops followed by fetal demise in majority of the cases. Antenatal diagnosis of this can be made by bidimensional echocardiography.Recently, the technological breakthrough of three-dimensional ultrasound (3D-US) offered new diagnostic tools for congenital heart defects, less dependent on the operator experience, when compared to two- dimensional ultrasound (2D-US). The spatio-temporal image correlation (STIC) technique is a new technique and by this we can acquire the fetal heart volume and its structures as a 4D cineloop sequence showing the complete cardiac cycle.

Purpose : To describe the features of Ebstein's anomaly through 2D and 3D ultrasonography with STIC Technique.

Material And Methods: Studied the ultrasonographic features of prenatally diagnosed Ebstein's anomaly using Philips Affinity 70 G Ultrasound Machine at Zenana Hospital, SMS Medical College, Jaipur. A convex volumetric transducer (4–8 MHZ) was used. The heart volume was acquired using Spatio-temporal image correlation (STIC) application. The fetal thorax was identified in a transverse plane showing the four cardiac chambers (four-chamber view). The region of interest (ROI) was set to contain the fetal heart and its vascular connections. The acquisition angle was defined at 25° and the capture time was set to 12.5 sec. After volume acquisition, the heart was analyzed in rendering mode, in static planes, and in cine loop sequences. Cardiac anatomy was assessed by thick slice method on a sagittal plane showing the valves.

INTRODUCTION

Congenital heart defects (CHDs) are the most common type of birth defect and are a leading cause of birth-defect associated morbidity and mortality[1]. The prevalence of CHDs is approximately 80 per 1000 live births[2]. Ebstein's anomaly is a type of CHD characterized by a malformation of the tricuspid valve and the right side of the heart[3]. Ebstein's is a rare CHD, accounting for less than 1% of all CHDs, with an estimated prevalence of approximately 0.5 per 10 000 live births[1].

A variety of cardiac abnormalities are associated with Ebstein's anomaly, including atrial septal defect, conduction system abnormalities, patent foramen ovale, pulmonary stenosis or atresia, and ventricular septal defect[1].

Echocardiography is the diagnostic test of choice to definitively diagnose Ebstein's anomaly. However, other modalities such as chest radiograph, electrocardiogram (ECG), and prenatal sonography are often the initial tests to detect the cardiac abnormality, leading to further evaluation.

Bidimensional ultrasound (2D-US) is the technique of choice for congenital heart defects screening, but it presents some limitations such as an operator-dependent exam, fetal position, oligohydramnios, real-time exam, and time-consuming image acquisition. Three-dimensional ultrasound (3D-US) depends less on the operator when used to evaluate the fetal heart. After the volume acquisition, the heart can

*Professor, **Assistant Professor, ***Senior Resident, ****Junior Resident
Department of Radiodiagnosis, Zenana Hospital, SMS Medical College, Jaipur, Rajasthan.
Corresponding Author
Dr. Abhinav Mathur
Senior Resident, Department of Radiodiagnosis, SMS Medical College, Jaipur

be analyzed in multiple planes, some of which cannot be obtained using 2D-US[4].

The Spatio-temporal image correlation (STIC) technique allows the acquisition of the fetal heart volume and its structures, and the visualization in the multiplanar mode or as a 4D cine loop sequence showing the complete cardiac cycle[5,6].

CASE:-A 24-year-old woman (G2P1A0) had come for a routine antenatal check-up with 6-month amenorrhea. She was otherwise asymptomatic. No history of maternal diabetes or any drug intake by patient. There was no significant family history of congenital heart disease.

USG FINDINGS:- The grayscale ultrasound examination revealed fetal cardiomegaly. The right atrium was found to be abnormally enlarged with the apical displacement of the posterior and septal leaflet. Colour Doppler examination revealed the presence of tricuspid regurgitation and TR jet arising from the middle of the right ventricle. The tricuspid valve leaflet was displaced caudally into the right ventricle. There is atrialization of the right ventricle and the functional right ventricle is small. The left side of the heart is compressed and small in size. The left ventricular outflow tract was normal.

DISCUSSION

In 1866, Wilhelm Ebstein described the autopsy

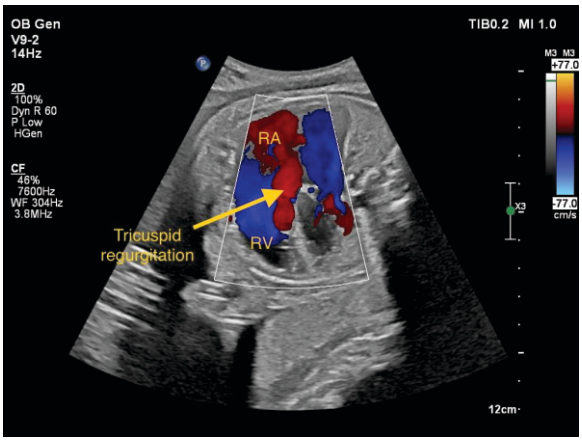

Image B -Colour Doppler showing jet of blood across the tricuspid valve during ventricular systole.

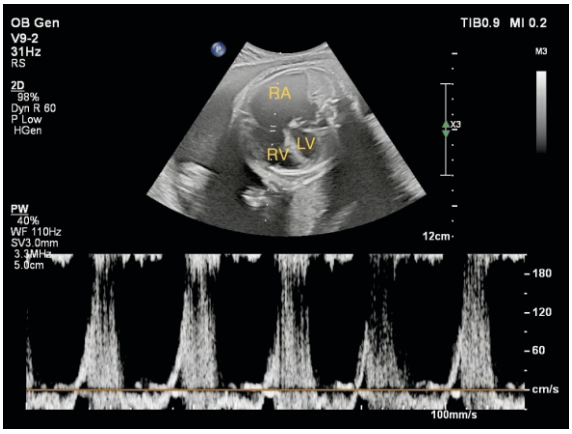

Image C- Showing increased velocity across the tricuspid valve of about 180 cm/sec.

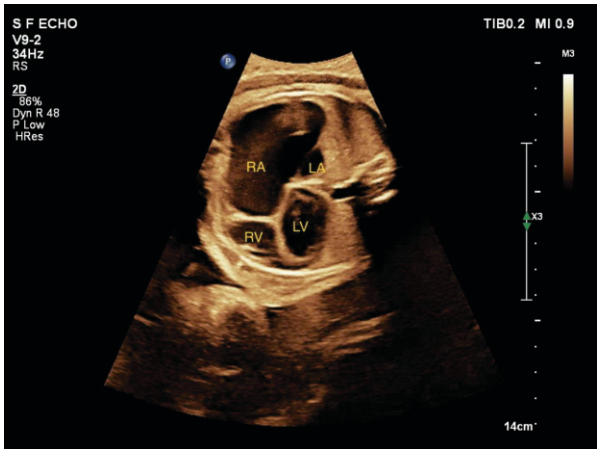

Image A- 2D echocardiography findings in a 24-week fetus with Ebstein's anomaly. Enlargement of the RA and displacement of the tricuspid valve with a small right ventricle. RA right atrium, RV right ventricle, LA left atrium, LV left ventricle.

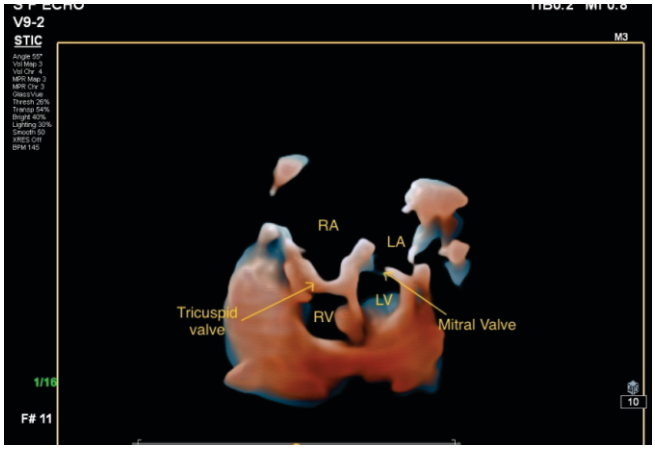

Image D- STIC rendering mode in a 24-week fetus with Ebstein's anomaly. The RA is enlarged and the tricuspid valve is displaced caudally with a shortening of the RV. STIC Spatio-temporal image correlation, RA right atrium, RV right ventricle.

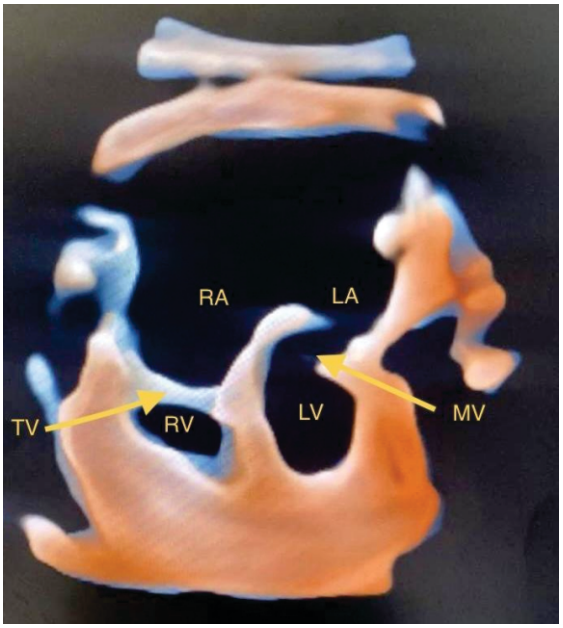

Image E- Showing the large right atrium (RA) and the small right ventricle (RV) are demonstrated in addition to the displaced attachment of the tricuspid (TV) in comparison to the mitral valves (MV).

findings of the tricuspid valve and right ventricle of a 19-year-old labourer who had had a history of cyanosis and dyspnoea since childhood[7].

Ebstein's anomaly develops during the first weeks of intrauterine life as the tricuspid valve fails to develop normally. During week 7, the atrioventricular valve leaflets begin to develop from the myocardial tissue of the ventricles by a process called delamination. By the end of week 12, the tricuspid valve is fully formed. In a normal heart, the tricuspid valve has three leaflets: anterior, posterior, and septal[8].

Ebstein's anomaly is a malformation of the tricuspid valve and right ventricle characterized by-

(1) Adherence of the septal and posterior leaflets to the underlying myocardium (failure of delamination, namely, splitting of the tissue by detachment of the inner layer during embryologic development);

(2) Downward (apical) displacement of the functional annulus (septal > posterior > anterior);

(3) Dilation of the "atrialized" portion of the right ventricle, with various degrees of hypertrophy and thinning of the wall;

(4) Redundancy, fenestrations, and tethering of the anterior leaflet; and

(5) Dilation of the right atrioventricular junction (true tricuspid annulus)[9].

The spectrum of malformation in Ebstein's anomaly may range from only minimal displacement of the septal and posterior leaflets to an imperforate membrane or muscular shelf between the inlet and the trabecular zones of the right ventricle. Many patients with Ebstein's anomaly have other structural cardiac anomalies and abnormalities of the cardiac conduction system, such as atrial septal defect, patent foramen ovale, pulmonary stenosis or atresia, and ventricular septal defects[10].

Most cases of Ebstein's anomaly are sporadic and the exact mechanism for the anomaly is not entirely understood. Case-control studies suggest genetic, reproductive, and environmental risk factors; for example, the anomaly is more common in twins, those with a family history of congenital heart disease, and those with maternal exposure to benzodiazepines. There is also a weak link between maternal lithium therapy and the presence of Ebstein's anomaly, although this rarely occurs[9].

Bidimensional echocardiography is the gold standard for the antenatal diagnosis of Ebstein's anomaly. The key findings are enlargement of the right atrium, dysplastic tricuspid valve with caudal implantation, tricuspid insufficiency, and atrial septal defects. Functional pulmonary atresia with confluent pulmonary truncus and arteries with an inverted blood flow is also frequent[6].

Spatio-temporal image correlation (STIC) is an advance in four-dimensional ultrasound, where the spatial and temporal information are combined to generate a dynamic volume of the fetal heart that can be analyzed in multiplanar mode or rendered planes. STIC allows the acquisition of a complete cardiac cycle in a dynamic volume shown as a cine loop sequence.

The ideal plane for capture is a transverse view of the fetal thorax (four-chamber view). During the second trimester, captured angles between 20° and 25° are sufficient to include the whole heart and its connections. Acquisition time varies from 7.5 to 15.0 sec, depending on the chosen angle and resolution[11,12].

In our case, the diagnosis was confirmed by bidimensional echocardiography. We tested the spatial motion covered by three-dimensional ultrasound. Enlargement of the right atrium and the displacement of

the tricuspid valve is clearly seen by the STIC technique. We used the thick slice method, considered the standard technique to evaluate the valve leaflets. Lower implantation of the tricuspid valve was clearly seen.

We suggest that the association of these new techniques with bidimensional echocardiography will increase the diagnostic test sensitivity for congenital heart defects during prenatal care.

REFERENCES

1. Yang, Q, Chen, H, Correa, A, Devine, O, Mathews, TJ, Honein, MA: Racial differences in infant mortality attributable to birth defects in the United States, 1989-2002. Birth Defects Res AClinMolTeratol 2006; 76(10):706–13.
2. Reller, M, Strickland, MJ, Riehle-Colarusso, TJ: Prevalence of congenital heart defects in metropolitan Atlanta, 1998-2005. J Pediatr 2008;153(6):807–13.
3. Cherry, C, DeBord, S, Moustapha-Nadler, N: Ebstein's anomaly: a complex congenital heart defect. ARON J 2009;89(6):1098–1114. doi:10.1016/j.aorn.2009.03.003.
4. DeVore GR, Medearis AL, Bear MB, Horestein J, Platt LD (1993) Fetal echocardiography: factors that influence imaging of the fetal heart during the second trimester of pregnancy. J Ultrasound Med 12:659–63
5. Gonçalves LF, Lee W, Chaiworapongsa T, Espinoza J, Schoen ML, Falkensammer P (2003) Four-dimensional ultrasonography of the fetal heart with spatiotemporal image correlation. Am J ObstetGynecol 189:1792–802
6. Viñals F, Poblete P, Giuliano A (2003) Spatio-temporal image correlation (STIC): a new tool for the prenatal screening of congenital heart defects. Ultrasound ObstetGynecol 22:388–94
7. Syamasundar Rao P, Other Tricuspid Valve Anomalies, In Long WA. Fetal and neonatal cardiology.WB Saunders, Philadelphia, pp 541-6 (1990).
8. Celermajer DS, Bull C, Till JA, Cullen S, Vassillikos VP, Sullivan ID, Allan L, Nihoyannopoulos P, Somerville J, Deanfield JE ,Ebstein's anomaly: presentation and outcome from fetus to adult. J Am Coll Cardiol.1994 Jan;23(1):170-6.
9. AttenhoferJost, C, Connolly, H, Dearani, J, Edwards, W, Danielson, G: Ebstein's anomaly. Circulation 2006;115(2):277–285. doi:10.1161/circulationaha.106.619338.
10. Dearani, JA, Danielson, GK: Congenital Heart Surgery Nomenclature and Database Project: Ebstein's anomaly and tricuspid valve disease. Ann ThoracSurg 2000;69(4 suppl): S106–S17.
11. Vinãls F, Poblete P, Giuliano A (2003) Spatio-temporal image correlation (STIC): a new tool for the prenatal screening of congenital heart defects. Ultrasound ObstetGynecol 22:388–94
12. Gonçalves LF, Lee W, Espinoza J, Romero R (2006) Examination of the fetal heart by four-dimensional (4D) ultrasound with spatiotemporal image correlation (STIC). Ultrasound ObstetGynecol 27:336–48